


IMAGING IN INTENSIVE CARE MEDICINE

Carbon dioxide angiography for detecting minor hemorrhage



Takero Terayama^{1*} , Shigeyoshi Soga², Hisashi Ikeuchi¹ and Yoshihiro Tanaka¹

© 2019 The Author(s)

A 78-year-old man was diagnosed to have left emphysematous pyelonephritis with disseminated intravascular coagulopathy. Incisional drainage and a pigtail catheter placement were performed as the initial surgical treatment. Four days after the operation, contrast-enhanced computed tomography revealed a massive hematoma around the left kidney; therefore, urgent angiography was performed.

The trunk of the left renal artery was engaged with a 4 Fr Shepherd's hook catheter. Digital subtraction

angiography (DSA) with an iodinated contrast agent demonstrated good anatomical images of renal arteries, but did not reveal hemorrhage. In contrast, CO₂-DSA with a wide imaging range demonstrated the bleeding site, but did not provide good anatomical images (Fig. 1a, b; Movie 1). The sequential use of both contrast agents, thus allowed to exploit the best of both methods: good anatomical images with the iodinated contrast agent and better localization of the bleeding with CO₂-DSA.

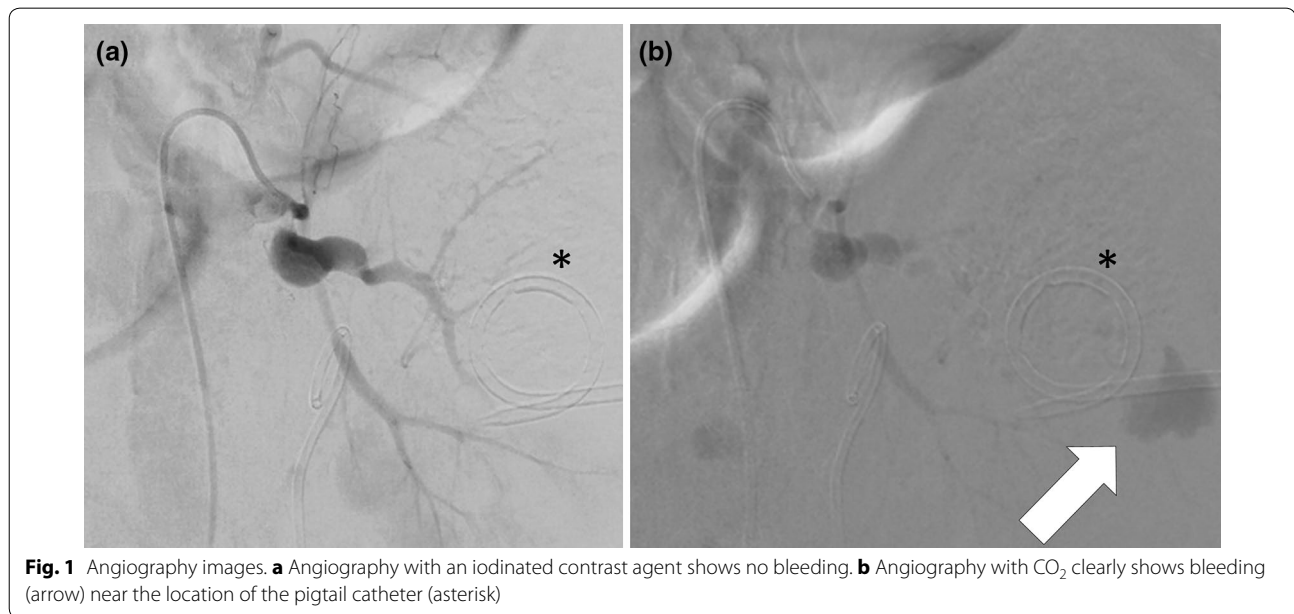


Fig. 1 Angiography images. **a** Angiography with an iodinated contrast agent shows no bleeding. **b** Angiography with CO₂ clearly shows bleeding (arrow) near the location of the pigtail catheter (asterisk)

*Correspondence: takero.for.medical.journal@gmail.com

¹ Department of Traumatology and Critical Care Medicine, National Defense Medical College Hospital, Namiki 3-2, Tokorozawa, Saitama 359-8513, Japan

Full author information is available at the end of the article

In addition to the kidney-friendly nature, the interest in using CO₂ angiography for the detection of minor hemorrhages is due to the low viscosity and high and rapid diffusion. Furthermore, the availability of the high-performance angiography system, which can reduce various artifacts, contributed to the good quality images of CO₂-DSA.

Electronic supplementary material

The online version of this article (<https://doi.org/10.1007/s00134-019-05796-7>) contains supplementary material, which is available to authorized users.

Author details

¹ Department of Traumatology and Critical Care Medicine, National Defense Medical College Hospital, Namiki 3-2, Tokorozawa, Saitama 359-8513, Japan.

² Department of Radiology, National Defense Medical College Hospital, Namiki 3-2, Tokorozawa, Saitama 359-8513, Japan.

Author contributions

TT, SS, HI, and YT contributed substantially to the writing of the manuscript.

Compliance with ethical standards

Conflicts of interest

The authors declare that they have no conflict of interest relevant to this manuscript.

Ethical approval

This study has been approved by the Commission for Medical Ethics of National Defense Medical College.

Informed consent

Written informed consent was obtained from the family of the patients.

Open Access

This article is distributed under the terms of the Creative Commons Attribution-NonCommercial 4.0 International License (<http://creativecommons.org/licenses/by-nc/4.0/>), which permits any noncommercial use, distribution, and reproduction in any medium, provided you give appropriate credit to the original author(s) and the source, provide a link to the Creative Commons license, and indicate if changes were made.

Publisher's Note

Springer Nature remains neutral with regard to jurisdictional claims in published maps and institutional affiliations.

Received: 11 August 2019 Accepted: 21 September 2019

Published online: 07 October 2019