

# Endovascular Therapy by CO<sub>2</sub> Angiography to Prevent Contrast-Induced Nephropathy in Patients With Chronic Kidney Disease: A Prospective Multicenter Trial of CO<sub>2</sub> Angiography Registry

Masahiko Fujihara,<sup>1,2\*</sup> MD, Daizo Kawasaki,<sup>3</sup> MD, PhD, Yoshiaki Shintani,<sup>4</sup> MD, Masashi Fukunaga,<sup>5</sup> MD, PhD, Tatsuya Nakama,<sup>6</sup> MD, Ryouji Koshida,<sup>7</sup> MD, Akihiro Higashimori,<sup>1</sup> MD, and Yoshiaki Yokoi,<sup>1</sup> MD, PhD, on behalf of the CO<sub>2</sub> Angiography Registry Investigators

**Objectives:** To assess the safety and efficacy of carbon dioxide (CO<sub>2</sub>) angiography-guided endovascular therapy (EVT) for renal, iliofemoral artery disease. **Background:** Patients with peripheral vascular disease (PVD) often have chronic kidney disease (CKD) and the use of iodinated contrast media may enhance the risk of contrast-induced nephropathy (CIN). Contrast volume reduction is an effective CIN preventive strategy. **Methods:** A prospective multicenter registry was developed and six clinical centers participated in the study. Patients with an estimated glomerular filtration rate (eGFR) of <60 ml/min/1.73 m<sup>2</sup> and stage-3 CKD were recruited between February 2012 and March 2013. CO<sub>2</sub> angiography-guided EVT was performed; incomplete CO<sub>2</sub> angiograms were supplemented by intravascular ultrasound, pressure wire, and/or minimal iodinated contrast media. The primary endpoint was a composite of freedom from renal events and freedom from major CO<sub>2</sub> angiography related complications. **Results:** This study included 98 patients with 109 lesions. The mean eGFR baseline was 35.2 ± 12.7 ml min<sup>-1</sup>. CO<sub>2</sub> angiography-guided angioplasty were performed in 16 renal arteries, 31 aortoiliac arteries, and 62 superficial femoral arteries. The technical success rate was 97.9%. Average CO<sub>2</sub> consumption was 281.4 ± 155.8 ml, average dose of iodinated contrast media was 15.0 ± 18.1 ml. Primary endpoint was 92.8% (91/98). Incidence of CIN was 5.1% (5/98) and CO<sub>2</sub> angiography-related complications occurred in 17.3% (17/98). Two cases (2%) developed severe, fatal, nonocclusive mesenteric ischemia (NOMI). **Conclusions:** This trial showed that CO<sub>2</sub> angiography-guided angioplasty was effective for preventing CIN, however, CO<sub>2</sub> angiography related complication was somewhat high. © 2014 Wiley Periodicals, Inc.

**Key words:** carbon dioxide angiography; endovascular therapy; chronic kidney disease

## INTRODUCTION

Indications for endovascular therapy (EVT) for peripheral vascular disease (PVD) are expanding. Elderly patients presenting with PVD, often have coexisting renal, cardiac, diabetic, and other medical

comorbidities. The number of patients with chronic kidney disease (CKD) complicated with PVD is significantly increasing. In these patients, iodinated contrast may enhance the risk of contrast-induced nephropathy (CIN). CIN is an acute renal injury and may lead to irreversible loss of renal function [1]. Following

<sup>1</sup>Department of Cardiology, Kishiwada Tokushukai Hospital, Kishiwada, Japan

<sup>2</sup>Department of Medicine and Biosystemic Science, Kyushu University Graduate, School of Medical Sciences, Fukuoka, Japan

<sup>3</sup>Department of Cardiology, Morinomiya Hospital, Osaka, Japan

<sup>4</sup>Department of Cardiology, Shin Koga Hospital, Kurume, Japan

<sup>5</sup>Cardiovascular Division, Hyogo College of Medicine, Nishinomiya, Japan

<sup>6</sup>Department of Cardiology, Miyazaki Medical Association Hospital, Miyazaki, Japan

<sup>7</sup>Department of Cardiology, Tokeidai Memorial Hospital, Sapporo, Japan

Conflict of interest: Nothing to report.

\*Correspondence to: Masahiko Fujihara, MD, Kishiwada Tokushukai Hospital, 4-27-1, Kamoricho, Kishiwada-city Osaka 596-8522, Japan. E-mail: masahiko-fujihara@themis.ocn.ne.jp

Received 9 April 2014; Revision accepted 2 November 2014

DOI: 10.1002/ccd.25722

Published online 7 November 2014 in Wiley Online Library (wileyonlinelibrary.com)

percutaneous cardiovascular intervention therapy, CIN was observed in 8–15% of total patients and 40–50% of high-risk patients depending on the prevalence of risk factors and used definition [2–4]. The most important effective preventive strategy for CIN is reduction in contrast media volume [5,6]. In the 1970s, Hawkins pioneered the intra-arterial application of carbon dioxide (CO<sub>2</sub>) gas angiography for high-risk patients who were allergic to iodinated contrast material and for those with renal insufficiency [7]. It is particularly advantageous in the treatment of atherosclerotic renal artery stenosis (ARAS) and infrarenal abdominal aortic aneurysms [8,9]. Although CO<sub>2</sub> angiography is considered to be a safe and efficacious method for the evaluation of PVD, the evaluation and treatment of renal artery and lower extremity arterial disease has not gained pervasiveness. With the advancements in interventional techniques and imaging technology over time, the utility of CO<sub>2</sub> angiography needs to be readdressed. Whether CO<sub>2</sub> angiography-guided EVT can be extended to a broader group of patients is uncertain. Moreover, no prospective study to date has been conducted to prove the efficacy and safety of CO<sub>2</sub> angiography-guided EVT.

Therefore we conducted a prospective, multicenter study to evaluate the feasibility and safety profile of CO<sub>2</sub> angiography-guided EVT and clarify the therapeutic role of a CO<sub>2</sub> angiography for EVT in CKD patients with renal artery stenosis (RAS), aortoiliac (AI) artery disease, and superficial femoral artery (SFA) disease.

## MATERIALS AND METHODS

### Study Design and Patient Population

This CO<sub>2</sub> angiography-guided renal and iliofemoral angioplasty trial was a prospective, multicenter, single-arm study. Between February 2012 and March 2013, 101 patients at six clinical centers participated in this study. Patients had either symptomatic peripheral artery disease (PAD) or ARAS with CKD. Patients underwent CO<sub>2</sub> angiography-guided EVT. We hypothesized that CO<sub>2</sub> angiography-guided EVT could decrease the amount of contrast medium required for angiography and would decrease the risk of CIN. This study conformed to the standard set by the Declaration of Helsinki and the study protocol was approved by our Ethics Review Board. Written informed consent was obtained from all patients before the procedure.

### Inclusion/Exclusion Criteria

Enrollment was restricted to patients aged  $\geq 20$  years who were planning to undergo EVT. Key inclusion criteria in these patients included CKD, which was

defined as estimated glomerular filtration rate (eGFR) of  $< 60$  ml/min/1.73 m<sup>2</sup>, [eGFR (male) =  $194 \times \text{serum creatinine}^{-1.094} \times \text{age}^{-0.287}$ ; eGFR (female) = eGFR (male)  $\times 0.739$ ], according to the formula recommended by the Japanese Society of Nephrology [10]. The main exclusion criteria were patients on renal replacement therapy and patients with only below-knee arterial disease.

### Indication of AI and/or SFA Intervention

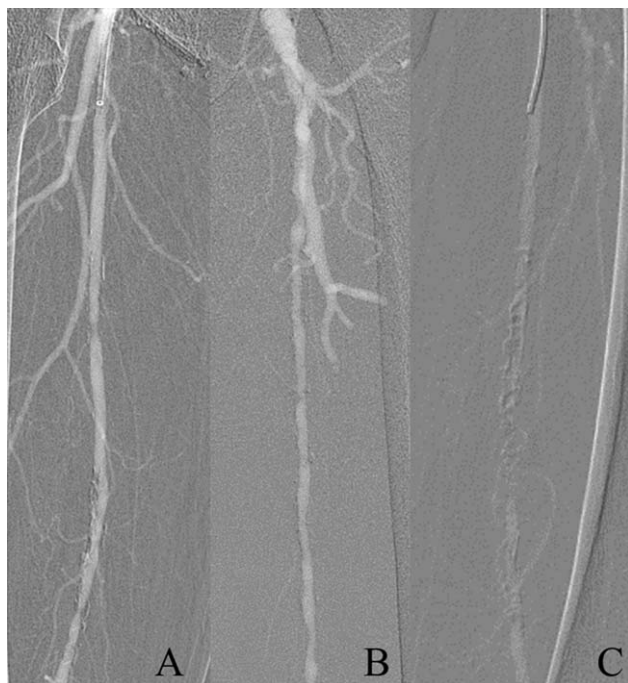All eligible patients were diagnosed with PAD, and had symptomatic AI and/or SFA disease. The patients had Rutherford category classes 2–6 with an Ankle Brachial Index (ABI) of  $< 0.9$  [11]. Duplex ultrasonography was used to diagnose the severity and location of the lesions. Significant stenosis was defined by Doppler indices with  $> 60\%$  diameter stenosis reference vessel diameter and/or a peak systolic velocity ratio  $> 2.5$  [12].

### Indication of RAS Intervention

Percutaneous renal artery stent implantation was indicated in patients who had either progressive renal insufficiency and/or refractory arterial hypertension. Refractory hypertension defined as systolic blood pressure (SBP)  $> 140$  mm Hg or diastolic blood pressure (DBP)  $> 90$  mm Hg, despite maximal doses of at least two antihypertensive agents [13]. Significant RAS was defined by Doppler indices with a peak systolic velocity (PSV) of  $> 219$  cm/s and a renal-to-aortic peak systolic velocity ratio  $> 3.5$  [14].

### Procedural Protocol

Unrestricted oral fluids were given to all patients and administration of nonsteroidal anti-inflammatory drugs (NSAIDs) was restricted for 2 days before the procedure and minimum 1 month after the procedure. Saline (0.90%) was given intravenously at a rate of 1 ml kg<sup>-1</sup> body weight per hour (0.5 ml kg<sup>-1</sup> for patients with left ventricular ejection fraction  $< 40\%$ ) for 6 hr before and 6 hr after procedure regardless of the iodinated contrast agent used [5]. Procedures were performed in dedicated angiographic suite under local anesthesia by usual standard technique. After guidewire crossing, the lesion was predilated with an optimal balloon. Stents were implanted in patients with a residual peak pressure gradient of  $> 10$  mm Hg, residual stenosis of  $> 30\%$ , and/or flow-limiting dissection following balloon dilatation. When necessary, intravascular ultrasound (IVUS), pressure wire, and/or a minimal amount (defined as  $< 40$  ml) of low-osmolality iodinated



**Fig. 1. Study Design: CO<sub>2</sub> angiography-guided EVT. Patient enrollment numbers: consented (101), protocol violation (3), AI group (31), SFA group (62), and RAS group (16).**

contrast media were used to identify the lesion and for stent placement.

### CO<sub>2</sub> Delivery Procedure

The CO<sub>2</sub> delivery system was used according to Kawasaki et al. [15]. The system consisted of a medical-grade CO<sub>2</sub> gas cylinder with a regulator; a regular, disposable, sterile plastic tube with a bacteria-removal filter; and a 50-ml delivery syringe. The gas was purged three to four times during collection to exclude room air contamination from the tube and the delivery syringe in the circuit and was filled with gas at a stationary flow of 2 l min<sup>-1</sup>. Forty milliliters of aspirated gas was filled into the delivery syringe; 30–40 cm<sup>3</sup> of CO<sub>2</sub> gas was manually injected into the vessel leaving about 5 cm<sup>3</sup> in the injection syringe. After the gas injection, the remaining gas and blood were carefully aspirated into the syringe. Gas injections were spaced ~30-sec apart.

### Quality of CO<sub>2</sub> Angiogram

Quality evaluation of CO<sub>2</sub> angiograms (CO<sub>2</sub>A) was assessed by the consensus of two experienced interventional physicians and classified into three types. In type I, the vessel and stenosis are completely visualized by the CO<sub>2</sub>A (Fig. 1A). In type II, the vessel can be evaluated but degree of stenosis cannot be measured; stenosis

assessments were made by either pressure wire or IVUS (Fig. 1B). In type III CO<sub>2</sub>A, no evaluation could be made. Interventions were made by minimal nonionic iodinated contrast media (defined as <40 ml) use with the help of IVUS and pressure wire (Fig. 1C).

### Primary and Secondary Endpoints

The primary composite endpoint was freedom from renal events (CIN, progressive renal insufficiency, and need for permanent renal-replacement therapy) and freedom from major CO<sub>2</sub> angiography-related complications. CIN was defined as an acute deterioration in renal function with a 25% or 0.5-mg dl<sup>-1</sup> increase in serum creatinine levels within 3 days after contrast administration [16]. Progressive renal insufficiency was defined as an eGFR reduction of ≥30% from the baseline. Complications related to CO<sub>2</sub> injection were defined as any specific morbidity during the follow-up period. Those were divided into major and minor complications. Major complications were defined that complications directly related to major adverse event (MAE). Minor complications were those not. MAE were defined as the occurrence of cardiac death, myocardial infarction, stroke, major amputation, target lesion revascularization, and/or postoperative death.

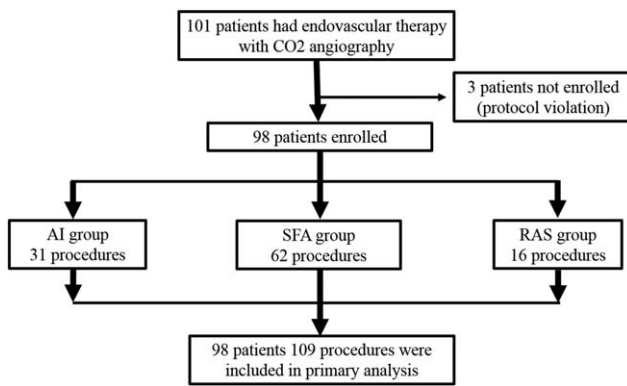
Secondary endpoints were freedom from MAE within a 3-month period, technical success, CO<sub>2</sub> angiography-related complications, quality evaluation of CO<sub>2</sub>A, and clinical outcomes. Technical success was defined as <30% residual stenosis.

### Follow-up

Clinical evaluation was conducted within 3 days after the procedure, at 1 and 3 months. These were clinical symptoms, renal function, MAE, Rutherford Category class, ABI, and lesion patency by duplex ultrasound.

### Statistical Analysis

All analyses were performed using JMP, version 10.0 (SAS Institute, Cary, NC). This was an observational, non-randomized study. Therefore, the statistical analysis was based on descriptive statistical techniques. Descriptive statistics are expressed in terms of frequencies, percentages, or means ± standard deviations. Where appropriate, categorical variables were evaluated by Fisher's exact test and continuous variables were assessed by the *t* test. When data before and after procedures were available, paired *t* tests were applied to compare repeated measures for continuous variables. *P* values of <0.05 were considered significant.



AI: Aorto-iliac, SFA: superficial femoral artery, RAS: Renal artery stenosis

**Fig. 2. Quality evaluation of CO<sub>2</sub> angiograms of SFA: A: Type I: vessel and stenosis were completely visualized. B: Type II: vessel can be evaluated but degree of stenosis cannot be measured. C: Type III: no evaluation could be made.**

## RESULTS

### Patients and Procedure Results

Of the 101 patients, three patients were excluded because of protocol violation, and 98 patients (73 men, 28 female, mean age  $75.6 \pm 7.9$  years, range 58–92 years) were analyzed. There were 31 patients with 29 lesions in the AI group, 62 patients with 62 lesions in the SFA group, and 16 patients with 16 lesions in the RAS group (Fig. 2).

Baseline patient clinical and lesion characteristics are summarized in Table I. The average pre eGFR was  $35.2 \pm 12.7$  ml/min/1.73 m<sup>2</sup> (range 4–59). The average preprocedure serum creatinine level was  $1.68 \pm 0.92$  mg dl<sup>-1</sup> (range 0.75–8.82 mg dl<sup>-1</sup>). Sixty percent of patients had stage-3 CKD, 40% had stage-4 or stage-5 CKD.

Procedural outcomes are summarized in Table II. Average CO<sub>2</sub> consumption was  $281.4 \pm 155.8$  ml (range 20–750 ml) and average dose of iodinated contrast media was  $15.0 \pm 18.1$  ml (range 0–70 ml).

### Primary and Secondary Endpoints

The primary composite endpoint of freedom from renal events and freedom from major CO<sub>2</sub> angiography-related complications was 92.8% (91/98). The value of eGFR before and after the EVT procedure is shown in Fig. 3. The mean eGFR was measured at 1–3 days, 1 month, and 3 months after the procedure, and did not show any statistical difference. The incidence of CIN was 5.1% (5/98). No case of worsening renal insufficiency and none of the patients required permanent renal replacement therapy. Among the 98 patients, in 17 cases (17.3%) were occurred CO<sub>2</sub>-related complications (Table III) Respiratory and neurological abnormality during follow up were not observed. Transient leg pain were noted in ten patients (10%) which subsided within 5 min, four patients (4.1%) complained of abdominal pain, in one patient, abdominal pain resulted in diarrhea which recovered completely following day. CO<sub>2</sub>-related MAE occurred in two patients (2.0%). These two patients complained of intractable abdominal pain and were diagnosed with severe nonocclusive mesenteric ischemia (NOMI). In spite of intensive treatment, both patients resulted in death within 2 days.

Case 1 was an 85-year-old man with Rutherford category class 3 with CKD stage-4 (eGFR = 18 ml min<sup>-1</sup>). The target lesion was a long occlusion of the left SFA. He was successfully recanalized using the ipsilateral antegrade approach without using iodinated

**TABLE I. Patient and Lesion Characteristics**

Patients characteristics	N = 98	Lesion characteristics	
Age (years old)	75.6 ± 7.88	<b>AI-group</b>	N = 31
Men n (%)	73 (74.4)	Rutherford class 2/3/4/5 (n)	9/19/0/3/0
Hypertension n (%)	93 (94.9)	Periprocedural ABI	0.73 ± 0.16
Diabetes n (%)	49 (50.0)	In-stent-restenosis n (%)	5 (5)
Dyslipidemia n (%)	62 (63.2)	Chronic total occlusion n (%)	5 (2)
Obesity n (%)	19 (19.3)	Lesion length (mm)	63 ± 38
Current smoker n (%)	26 (26.5)	<b>SFA-group</b>	N = 62
Heart failure n (%)	19 (19.4)	Rutherford class 2/3/4/5 (n)	11/33/5/12/1
Coronary artery disease n (%)	65 (66.3)	Periprocedural ABI	0.66 ± 0.24
Cerebrovascular disease n (%)	39 (39.8)	In-stent-restenosis n (%)	18 (29)
Serum Cr (mg dl <sup>-1</sup> )	1.68 ± 0.92	Chronic total occlusion n (%)	23 (37)
eGFR (ml min <sup>-1</sup> )	35.2 ± 12.7	Lesion length (mm)	149 ± 81
CKD stage3A/3B/4/5 (%)	29/30/35/4	<b>RAS-group</b>	N = 16
BNP (pg dl <sup>-1</sup> )	182.9 ± 240	Uncontrolled hypertension	10 (62.5)
		In-stent-restenosis n (%)	2 (12.5)
		Peak systolic velocity by duplex	349 ± 97.3
		Renal-aortic flow ratio	5.4 ± 1.89

TABLE II. Procedure Data

Procedure outcomes	All; N = 98	AI group; N = 31	SFA group; N = 62	RAS group; N = 16
Technical success <i>n</i> (%)	96 (97.9)	30 (96.7)	61 (98.4)	16 (100)
Use of IVUS <i>n</i> (%)	15 (48.4)	15 (48.4)	37 (59.7)	4 (25.0)
Use of pressure wire <i>n</i> (%)	11 (35.5)	11 (35.5)	5 (8.1)	13 (81.3)
Distal protection <i>n</i> (%)	6 (6.1)	2 (6.4)	5 (8.1)	0 (0)
Fluoroscopy time (min)	23 ± 17	27 ± 21	23 ± 20	17 ± 9
Contrast media volume (ml)	15.0 ± 18.1	11.5 ± 16.9	15.3 ± 19.9	19.8 ± 13.0
CO <sub>2</sub> injection volume (ml)	281.4 ± 156	262.3 ± 158	324.9 ± 157	205.6 ± 145

contrast media, by injecting 750 ml of CO<sub>2</sub>. At 3 hr of post procedure, the patient complained of severe abdominal pain and gas was found in the portal vein by plain abdominal X-ray examination. As there was no evidence of occlusive disease of the visceral arterial system, the patient was diagnosed with NOMI. Even after exploratory laparotomy, the patient could not be saved and died on the second day. Case 2 was a 72-year-old man with Rutherford category class 4 with stage-4 CKD (eGFR = 18 ml min<sup>-1</sup>). Right iliac artery stenosis was successfully stented by retrograde approach and left SFA stenosis was successfully treated by balloon and stent via the crossover approach with 180 ml of CO<sub>2</sub> injection and no contrast media use. Case 2 had a similar clinical course to case 1 and died on the second day.

Technical success was obtained in 97.9% patients (96/98 lesions). Two unsuccessful cases were a result of failure in guidewire crossing for chronic occlusive lesions.

MAE occurred in four patients. Above described two patients had NOMI (2%, 2/98). Major amputation of a limb was required for one case (1%, 1/98). The fourth case received clinically driven target lesion revascularization (1%, 1/98) for restenosis with recurrent intermittent claudication during the follow-up period.

The quality evaluation of CO<sub>2</sub>A is shown in Table IV. Type I CO<sub>2</sub>A were obtained in 62.9% of patients in the SFA group. Type II CO<sub>2</sub>A were most commonly observed among patients in the AI group (61.3%); and

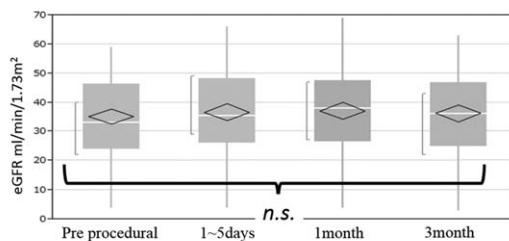
type III were most commonly seen in patients with RAS (43.7%). Twenty-five chronic total occlusions were evaluated as well. Type I angiograms were obtained in 56% of these lesions. Type II angiograms were achieved in 36% and Type III in the remaining 8%.

Table V shows clinical outcomes of the patients. At 3 months, Rutherford category class and ABI were significantly improved in both the AI and SFA groups. Systolic blood pressure was significantly improved in RAS group.

## DISCUSSION

### Efficacy of CO<sub>2</sub> Angiography-guided EVT

There is a continual increase in the number of CIN cases because of the increase in the number of interventional procedures requiring contrast administration in aged patients with CKD. The most effective preventive strategy for CIN is to reduce the volume of iodinated contrast media. The other well-known preventive methods include the administration of N-acetylcysteine, ascorbic acid, sodium bicarbonate, and prophylactic hemofiltration. However, the effectiveness of these CIN preventive strategies remains controversial [17–20]. There is no single evidence-based specific effective treatment for the prevention of CIN that is well established yet. The risk of CIN was directly associated with increasing iodinated contrast volume adjusted for renal function. Cigarroa et al. used an empirical formula of 5 ml of contrast material multiplied by body weight (kg) divided by serum creatinine (mg dl<sup>-1</sup>) to set a contrast volume limit in their study [21]. Gurm et al. reported that a contrast volume restricted to less than thrice and preferably twice the calculated creatinine clearance might be valuable in reducing the risk of CIN [6]. CIN in patients with CKD undergoing EVT, it is crucial to substantially decrease the volume of iodinated contrast administered. Furthermore, in patients with severe allergic reactions, iodinated contrast-guided EVT may not even be feasible. CO<sub>2</sub> angiography has now been used for decades in these settings; however, it has not gained popularity



N	98	98	93	88
eGFR (ml/min/1.73m <sup>2</sup> )	35.2 ± 12.8	36.7 ± 14.4	37.1 ± 13.8	36.3 ± 13.9

Fig. 3. eGFR following CO<sub>2</sub> angiography.

TABLE III. Prevention of CIN and CO<sub>2</sub>-Related Complications

	Total; N = 98	AI group; N = 31	SFA group; N = 64	RAS group; N = 16
CIN n (%)	5 (5.1)	2 (6.4)	5 (7.8)	0 (0.0)
<b>Complications related to CO<sub>2</sub> injection</b>				
Total n (%)	17 (17.3)	7 (22.6)	10 (15.6)	3 (18.8)
<b>Minor complications</b>				
Leg pain n (%)	8 (8.1)	2 (6.4)	7 (10.9)	0 (0)
Abdominal pain n (%)	6 (6.1)	3 (9.7)	1 (1.6)	3 (18.8)
Diarrhea	1 (1.0)	1 (3.2)	0 (0)	0 (0)
<b>Major complications</b>				
Non-occlusive mesenteric ischemia (NOMI)	2 (2.0)	1 (3.2)	2 (3.1)	0 (0)

as an aid to endovascular interventions in the renal and infrainguinal arteries. There are three primary reasons. First, there may be insufficient high-quality digital subtraction angiography systems available. Second, the use of a gas rather than a liquid contrast agent may be unfamiliar to most vascular interventionists. Third, there may be some concern about bowel ischemia due to the trapping of CO<sub>2</sub> gas in celiac, superior and/or inferior mesenteric arteries. The average pre procedure eGFR observed in this study was 35.2 ml min<sup>-1</sup>. However, this study shows that the overall incidence of CIN in patients undergoing EVT remains low at 5.1%. The primary reason for this low incidence of CIN is minimal contrast use. The average volume of iodinated contrast was 15.0 ml, with the mean volume of CO<sub>2</sub> was 281 ml.

### Safety of CO<sub>2</sub> Angiography

Injection of CO<sub>2</sub> carries several potential risks. The risk of gas delivery into the vessel is still undetermined. Moreover, the safety volume for CO<sub>2</sub> injection has not been reported. There are also potential risks of CO<sub>2</sub> administration. These are excessive volume administration, inappropriate delivery, and air contamination of CO<sub>2</sub> gas. Kawasaki et al. reported that 14.6% of patients with CO<sub>2</sub> angiography complained of transient lower limb pain and 3% patients experienced transient abdominal pain. However, no major complications occurred in their study [15]. Madhusudhan et al. reported that severe leg pain was complained of 4.8% and mild leg pain in 28.6 % of patients during the CO<sub>2</sub> injection [22]. Eighteen percent of examinations were discontinued due to the leg pain when high volumes and flow rates were used. In our study, CO<sub>2</sub>-related complications were observed in 17 cases (17.3%). In

TABLE IV. Quality Evaluation of CO<sub>2</sub> Angiograms

Quality of CO <sub>2</sub> angiogram	Type I	Type II	Type III	P value
AI group n (%)	7 (22.6)	19 (61.3)	5 (16.1)	
SFA group n (%)	39 (62.9)	22 (35.5)	1 (1.6)	<0.0001*
RAS group n (%)	5 (31.2)	4 (25.0)	7 (43.7)	

15 cases (15.3%) complications were minor and transient incidence. These were leg pain in eight patients (8.1%), abdominal pain in six (6.1%) and one patient had diarrhea (1%). Two patients (2.04%) developed severe CO<sub>2</sub>-related NOMI resulting in death within 2 days of their index procedure. In case 1, a high volume of CO<sub>2</sub> (750 ml) was consumed because of the long occlusion of SFA. In the second case, 180 ml of CO<sub>2</sub> gas was injected, which is considered to be the safety dose range of CO<sub>2</sub> gas injection. These two cases suggest that CO<sub>2</sub> angiography carries the risk of NOMI whether small or large volumes of CO<sub>2</sub> are delivered. From these observations, we speculated that main cause of NOMI was excessive amount of CO<sub>2</sub> injection in case1. In case 2, the injected CO<sub>2</sub> volume was small, but retained CO<sub>2</sub> gas in the iliac artery could be the potential reason of mesenteric ischemia. Another plausible reason is the injection of contaminated CO<sub>2</sub> gas. Even after CO<sub>2</sub> is filtered in a closed circuit, complete air contamination may not always be prevented.

Based on this CO<sub>2</sub> study, when the patients complained of abdominal pain, further CO<sub>2</sub> injection should be avoided until complete resolution of symptoms is achieved and confirmation of absence of gas retention in the arterial system is obtained. The timing of each of the next injections should be carefully planned and delivered while carefully monitoring clinical symptoms.

TABLE V. Clinical Outcomes

	Preprocedure	3 months	P value
<b>AI group</b>			
ABI	0.73 ± 0.16	0.88 ± 0.15	<0.0001**
Rutherford category	2.92 ± 0.15	1.89 ± 0.20	<0.0001**
<b>SFA group</b>			
ABI	0.66 ± 0.24	0.83 ± 0.21	<0.0001**
Rutherford category	3.36 ± 1.03	2.19 ± 1.45	<0.0001**
<b>RAS group</b>			
Systolic blood pressure (mm Hg)	142.3 ± 24.8	136.3 ± 21.8	0.048*
Peak systolic velocity (cm sec <sup>-1</sup> )	349 ± 97.3	120 ± 48.9	<0.0001**

### Quality Evaluation of CO<sub>2</sub>A

Type I or II CO<sub>2</sub>A could be of sufficient high quality to be used as an adequate alternative to iodinated contrast. Either type I or II CO<sub>2</sub>A were obtained in 98.4, 83.9, and 56.2% of patients in the SFA, AI and RAS groups respectively. In the latter group, complementary imaging modalities were necessary to complete the intervention. The main reason for observing the highest percentage of type I CO<sub>2</sub>A among patients in the SFA group is the absence of the interference provided by bowel loops and gas (seen more frequently in patients undergoing AI and RAS procedures), suggesting that CO<sub>2</sub>A can effectively replace traditional iodinated contrast in selected cases. We obtained good images of CTO lesions with CO<sub>2</sub> angiography. Because of CO<sub>2</sub> spreading more rapidly than iodinated contrast media, we can see the distal edge of CTO through the collateral circulation.

### Study Limitations

The single arm registry design without a control group, leads to inherent shortcomings. It is also worth noticing that we did not standardize the method, volume and rate of CO<sub>2</sub> injection among the participating sites, which may influence the occurrence of some of the secondary endpoints. About various types of vessels (small vessels, CTO's with collaterals, and calcifications lesions) were needed further consideration. Furthermore, whether or not to routinely use anticoagulants and/or vasodilators, as well as which ones and at what doses to prevent NOMI during CO<sub>2</sub> guided interventions, remains the subject of further investigation.

### CONCLUSION

This trial showed clinical efficacy of CO<sub>2</sub> angiography-guided EVT in renal and iliofemoral arteries in patients with CKD. A high procedural success rate was obtained with a minimum amount of iodinated contrast volume. Low incidence of CIN was confirmed in CO<sub>2</sub> angiography-guided EVT. However, CO<sub>2</sub> angiography carries the risk of severe NOMI, which results in high rates of mortality. Cautious use of CO<sub>2</sub> angiography is warranted.

### ACKNOWLEDGMENTS

The authors thank Drs Ryota Fukuoka, Kojiro Miki, Michinao Tan, and Keisuke Fukuda for their contributions of catheterization and patients management; Dr. Keita Odashiro, MD, Department of Medicine and Biomedical Science, Kyushu University hospital, who provided data management center; and Dr. Toru Mar-

uyama, MD, Prof, Faculty of Arts and Science, Kyushu University, who provided safety committee process.

### REFERENCES

1. Tepel M, Aspelin P, Lameire N. Contrast-induced nephropathy: A clinical and evidence-based approach. *Circulation* 2006;113:1799–1806.
2. McCullough PA, Wolyn R, Rocher LL, Levin RN, O'Neill WW. Acute renal failure after coronary intervention: Incidence, risk factors, and relationship to mortality. *Am J Med* 1997;103:368–375.
3. Rashid ST, Salman M, Myint F, Baker DM, Agarwal S, Sweny P, Hamilton G. Prevention of contrast-induced nephropathy in vascular patients undergoing angiography: A randomized controlled trial of intravenous *N*-acetylcysteine. *J Vasc Surg* 2004;40:1136–1141.
4. Waybill MM, Waybil PN. Contrast media-induced nephrotoxicity: Identification of patients at risk and algorithms for prevention. *J Vasc Interv Radiol* 2001;12:3–9.
5. Briguori C, Airoldi F, D'Andrea D, Bonizzoni E, Morici N, Focaccio A, Michev I, Montorfano M, Carlino M, Cosgrave J, Ricciardelli B, Colombo A. Renal insufficiency following contrast media administration trial (REMEDIAL): A randomized comparison of 3 preventive strategies. *Circulation* 2007;115:1211–1217.
6. Gurm HS, Dixon SR, Smith DE, Share D, Lalonde T, Greenbaum A, Moscucci M. Renal function-based contrast dosing to define safe limits of radiographic contrast media in patients undergoing percutaneous coronary interventions. *J Am Coll Cardiol* 2011;58:907–914.
7. Hawkins IF. Carbon dioxide digital subtraction arteriography. *Am J Roentgenol* 1982;139:19–24.
8. Beese RC, Bees NR, Belli AM. Renal angiography using carbon dioxide. *Br J Radiol* 2000;73:3–6.
9. Chao A, Major K, Kumar SR, Patel K, Trujillo I, Hood DB, Rowe VL, Weaver FA. Carbon dioxide digital subtraction angiography assisted endovascular aortic aneurysm repair in the azotemic patient. *J Vasc Surg* 2007;45:451–458.
10. Ando Y, Ito S, Uemura O, Kato T, Kimura G, Nakao T, Hattori M, Fukagawa M, Horio M, Mitarai T; Japanese Society of Nephrology. CKD clinical practice guidebook. The essence of treatment for CKD patients. *Clin Exp Nephrol* 2009;13:191–248.
11. Rutherford RB, Becker GJ. Standards for evaluating and reporting the results of surgical and percutaneous therapy for peripheral arterial disease. *J Vasc Interv Radiol* 1991;2:169–174.
12. Bosiers M, Torsello G, Gissler HM, et al. Nitinol stent implantation in long superficial femoral artery lesions: 12-month results of the durability I study. *J Endovasc Ther* 2009;16:261–269.
13. Jaff MR, Bates M, Sullivan T, Popma J, Gao X, Zaugg M, et al. Significant reduction in systolic blood pressure following renal artery stenting in patients with uncontrolled hypertension: Results from the HERCULES trial. *Catheter Cardiovasc Interv* 2012;80:343–350.
14. Kwarada O, Yokoi Y, Takemoto K, Morioka N, Nakata S, Shiotani S. The performance of renal duplex ultrasonography for the detection of hemodynamically significant renal artery stenosis. *Catheter Cardiovasc Interv* 2006;68:311–318.
15. Kawasaki D, Fujii K, Fukunaga M, Masutani M, Nakata A, Masuyama T. Safety and efficacy of endovascular therapy with a simple homemade carbon dioxide delivery system in patients with iliofemoral artery diseases. *Circ J* 2012;76:1722–1728.

16. Thomsen HS, Morcos SK. Contrast media and the kidney: European society of urogenital radiology (ESUR) guidelines. *Br J Radiol* 2003;76:513–518.
17. Spargias K, Alexopoulos E, Kyrzopoulos S, Iokovis P, Greenwood DC, Manginas A, Voudris V, Pavlides G, Buller CE, Kremastinos D, Cokkinos DV. Ascorbic acid prevents contrast-mediated nephropathy in patients with renal dysfunction undergoing coronary angiography or intervention. *Circulation* 2004;110:2837–2842.
18. Isenbarger DW, Kent SM, O'Malley PG. Metaanalysis of randomized clinical trials on the usefulness of acetylcysteine for prevention of contrast nephropathy. *Am J Cardiol* 2003;92:1454–1458.
19. Hafiz AM, Jan MF, Mori N, Shaikh F, Wallach J, Bajwa T, Allaqaband S. Prevention of contrast-induced acute kidney injury in patients with stable chronic renal disease undergoing elective percutaneous coronary and peripheral interventions: Randomized comparison of two preventive strategies. *Catheter Cardiovasc Interv* 2012;79:929–937.
20. Marenzi G, Marana I, Lauri G, Assanelli E, Grazi M, Campodonico J, Trabattoni D, Fabbicocchi F, Montorsi P, Bartorelli AL. The prevention of radiocontrast-agent-induced nephropathy by hemofiltration. *N Engl J Med* 2003;349:1333–1340.
21. Cigarroa RG, Lange RA, Williams RH, Hillis LD. Dosing of contrast material to prevent contrast nephropathy in patients with renal disease. *Am J Med* 1989;86:649–652.
22. Madhusudhan KS, Sharma S, Srivastava DN, Thulkar S, Mehta SN, Prasad G, Seenu V, Agarwal S. Comparison of intra-arterial digital subtraction angiography using carbon dioxide by “home made” delivery system and conventional iodinated contrast media in the evaluation of peripheral arterial occlusive disease of the lower limbs. *J Med Imaging Radiat Oncol* 2009;53:40–49.