

Vascular Imaging with Carbon Dioxide: Confidence in a Safe, Efficacious, User-Friendly System

James G. Caridi, MD, FSIR¹

¹ Division of Vascular and Interventional Radiology, Department of Radiology, Tulane University Medical School, New Orleans, Louisiana

Address for correspondence James G. Caridi, MD, FSIR, 8327 SW 17th Lane, Gainesville, FL 32607 (e-mail: jimcaridi@gmail.com).

Semin Intervent Radiol 2015;32:339–342

Abstract

Carbon dioxide (CO₂) has been used as an imaging agent since the early 1900s. The intravascular use of CO₂ for imaging began in the 1960s. Its use was limited, as the available technology for imaging and safe delivery was poor. Even until today its use as an imaging agent has not reached its potential because of non-user friendly and cumbersome delivery methods. Confusing tanks, valves, and assembly of do-it-yourself systems create an aversion to its use. As an invisible agent with properties vastly different from liquid contrast, well-seasoned interventionalists are hesitant to use it because of perceived often unrealistic potential complications. Despite many of the advantages of a gaseous imaging agent, insecurity has translated to its lack of use and availability to the benefit of patients. With the development of the new CO₂mmander/AngiAssist delivery system (AngioAdvancements, Inc; Ft. Meyers, FL), a compact, unwieldy, easily understood, closed system that does not require assembly is replacing the various makeshift systems in the CO₂ community. This system combines a small multiuse disposable cylinder, compact regulator, and a dual syringe delivery system to the patient. A unique proprietary valve (K-valve) prevents the possibility of CO₂ overload during delivery. Because of one-way valves and the prepackaged complete setup, operator error and air contamination with inadvertent connections are eliminated. Noncompressed CO₂ is administered in the volume of choice in a nonexplosive manner. This simple, yet safe and effective, delivery system will undoubtedly promote the greater use of intravascular CO₂. This in turn will translate into improved patient care in both the diagnostic and interventional arena.

Keywords

- ▶ contrast
- ▶ vascular imaging
- ▶ CO₂
- ▶ carbon dioxide
- ▶ interventional radiology

Objectives: Upon completion of this article, the reader will be able to identify a new carbon dioxide delivery system for intravascular imaging. The attributes of the new system translate into improved patient care through the expanded use of a safe, simple, user friendly system.

Accreditation: This activity has been planned and implemented in accordance with the Essential Areas and Policies of the Accreditation Council for Continuing Medical Education (ACCME) through the joint providership of Tufts

University School of Medicine (TUSM) and Thieme Medical Publishers, New York. TUSM is accredited by the ACCME to provide continuing medical education for physicians.

Credit: Tufts University School of Medicine designates this journal-based CME activity for a maximum of **1 AMA PRA Category 1 Credit**[™]. Physicians should claim only the credit commensurate with the extent of their participation in the activity.

Issue Theme New Tools, Techniques, and Technologies; Guest Editor, Hector Ferral, MD

Copyright © 2015 by Thieme Medical Publishers, Inc., 333 Seventh Avenue, New York, NY 10001, USA.
Tel: +1(212) 584-4662.

DOI <http://dx.doi.org/10.1055/s-0035-1564813>.
ISSN 0739-9529.

Carbon dioxide (CO₂) has been used as an imaging agent since the early 1900s.¹⁻³ Initially it was used in the abdomen and retroperitoneum, and then in the 1960s, it was used intravenously to determine the presence of pericardial effusion.^{4,5} In 1976, an inadvertent injection of gas into the celiac axis lead Dr. Hawkins to embark upon using CO₂ as an intravascular imaging agent.⁶ Unfortunately, the technology at that time was not sufficient and this hampered the visualization and usefulness of CO₂ for imaging.

With the development of digital subtraction angiography and multiple positional procedure tables, the use of CO₂ as an imaging agent progressed rapidly. CO₂ was found to have several advantages over iodinated contrast.^{7,8} Some of these include the fact that it is nonallergic and non-renal toxic. Its low viscosity, which is 1/400 that of liquid contrast, allows for use in small catheters, injection through catheters with the wire in place, detection of acute hemorrhage, and portal vein visualization. Its ability to reflux centrally demonstrates catheter position much more readily than typical contrast. These benefits provide many clinical advantages for CO₂ when used alone or in combination with iodinated contrast.

Despite the many advantages and uniqueness of a gaseous imaging agent, it has failed to proliferate to the potential benefit for so many ideal patients. This has been due mostly to the fact that the gas is invisible and raises operator concern about room air contamination. This factor is exacerbated by the lack of a consistent fool proof delivery system. In addition, the large gaseous cylinders with multiple valves are not only cumbersome but are concerning and unfamiliar to most individuals who typically use liquid contrast.

At its inception, CO₂ was initially removed directly from the cylinder with a syringe and delivered directly to the patient. Because of potential room air contamination and explosive delivery, this was not the most ideal method of administration. Many different homemade versions for delivery of CO₂ using stopcocks and tubing were relied upon.⁹ In an attempt to simplify the delivery of CO₂, a few specific dedicated mechanical injectors have been developed; however, these were cumbersome, expensive, and commonly unreliable. A bag system was developed which was useful

but did require assembly and typically took significant time to purge the system of room air.⁸ Physicians most familiar with CO₂ delivery realized that the best system would be the one that is quick, simple, reliable, no assembly required, and closed to room air. In addition, a limit on the number of stopcocks would be useful to avoid human error. It was also imperative to avoid direct contact from the large pressurized CO₂ cylinder and the intravascular structures of the patient.

Considering the requirements for safe, effective delivery of CO₂ into the vascular system as well as experience with many of the previous delivery systems, an attempt was made to develop a system that is compact, simple, user friendly, does not require assembly, and most of all safe and efficacious. The primary goal was to create a system that operators, both veteran and nonveteran, could understand and feel confident in so that the advantages of CO₂ as an imaging agent could be used to benefit their patients.

A Novel Device

A compact CO₂ medical gas cylinder (→ Fig. 1), portable low-pressure regulator, and pre-assembled delivery system was manufactured to achieve the aforementioned primary goal. In this system, there is the use of a compact 10,000-mL laboratory grade CO₂ cylinder. The cylinders are triple-washed before filling. The cylinder has special threads which are unique to the regulators for which it is inserted. This prevents the insertion of inappropriate gas canisters to the regulator. The laboratory grade quality of CO₂ exceeds the recommended medical grade purity for CO₂ vascular imaging. The cylinder is disposable eliminating the initial difficulties and complications of reusable cylinders and large “disposable” cylinders that are not depleted over a long period of time. Despite being described as reusable, many of the large tanks are not depleted allowing bacteria, molds, mildew, carbonic acid, rust and other contaminants dwell within. Large tanks are also cumbersome and tip easily, which can damage regulators and valves and preclude or delay use during a procedure. The smaller cylinders with the CO₂mmander system (AngioAdvancements, Inc; Ft. Meyers, FL) can be



Fig. 1 Compact, disposable CO₂ cylinder containing 10,000 mL of laboratory grade carbon dioxide. Threads (arrow) are unique to the CO₂mmander regulator preventing attachment of other gaseous cartridges.

stored in a sterile bag and placed in a position of convenience. The volume of one cylinder can be used typically for numerous patients depending on the amount of CO₂ used per case. This new cylinder removes the large bulky cumbersome tanks with excessive volumes and potential contaminants; it alone minimizes the system so that it is easier to use and maintain quality control.

The new cylinder is attached to the CO₂mmander device (► **Fig. 2**). This device is a portable, hand-held regulator for the delivery of medical-grade (or better) CO₂ gas. It is a regulator that has been downsized for convenience. The CO₂mmander device uses various components and pneumatics to convert medical grade CO₂ liquid to gas and transfers the CO₂ to the delivery system in a controlled manner. Up until now, the typical tanks in use are under high pressure making them impractical for downregulating delivery to anything other than a large reservoir. This often leads to explosive delivery which potentially has negative consequences. The CO₂mmander device can be regulated as low as 1 psi (ranging from 1 to 30 psi). This allows delivery of CO₂ to something as small as a 5-mL syringe providing total flexibility and treatment options. In addition, all of the components of the Co2mmander device including the gauges and valves are contained within a durable airplane aluminum shell which protects them from breakage and potential downtime in case it is mishandled.

The delivery system, termed the *AngiAssist* (► **Fig. 3**) is preassembled and consists of two one-way valves, a reservoir



Fig. 2 Petite, CO₂mmander regulator that converts liquid CO₂ in the cylinder to a gas at low pressures unlike the large cumbersome tanks. Also, as opposed to the traditional tanks, all components including the valve are internalized and protected by an airline aluminum shell making it more durable.

syringe, a delivery syringe, a proprietary K-valve, and afferent and efferent tubing. There is a one-way valve which connects to the CO₂ regulator. This cannot be attached to the delivery catheter, thus avoiding any inappropriate connections. From here, there is afferent tubing which connects to a K-valve, which has three ports (► **Fig. 4**). The uniqueness of the K-valve is that it has 60-degree directional flow; it cannot provide

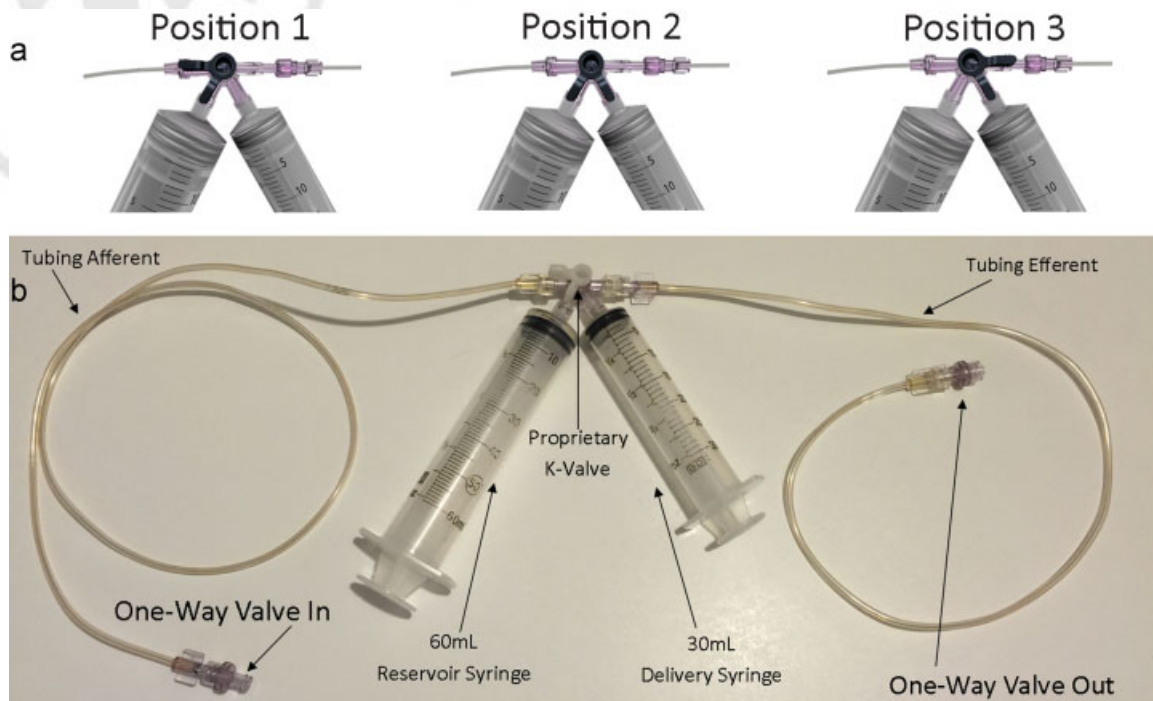


Fig. 3 (a) Proprietary K-valve that precludes direct flow of CO₂ from cylinder to patient. Position 1 allows gas from CO₂mmander to the reservoir syringe. Position 2 permits passage from the reservoir to the delivery syringe. Finally, position 3 allows gas to pass from the delivery syringe to the delivery catheter. (b) The *AngiAssist* consists of two one-way valves that not only prevent retrograde contamination but also prevent inadvertent connection to the CO₂mmander and delivery syringe. There is afferent tubing from the CO₂mmander to the K-valve. The K-valve directs flow from the afferent tubing to the reservoir syringe, the reservoir syringe to the delivery syringe, and the delivery syringe to the efferent tubing and to the patient.



Fig. 4 Proprietary K-valve. Gas can only traverse in the direction of the stems or 60 degrees.

180-degree flow and the CO₂ regulator can never transfer gas directly to the patient. The stems on the valve demonstrate the 60-degree direction of flow to reduce inappropriate delivery.

The first port of the K-valve is connected to a 60-mL reservoir syringe. This syringe is Luer-locked and can be removed if greater volume is necessary. The next port located 60 degrees from the reservoir syringe is connected to the delivery syringe. A 30-mL syringe is included but can be exchanged. Gas is transferred in one step from the regulator to the reservoir syringe. The K-valve is then turned to the delivery syringe and the desired amount of CO₂ is transferred from the reservoir to the delivery syringe. Purists would suggest pushing the gas from the reservoir to the delivery syringe to avoid the small possibility of aspirating gas through K-valve or similar stopcock system. When the appropriate amount of desired CO₂ is in the delivery syringe, the K-valve is turned toward the efferent tubing. The efferent tubing has a distal one-way valve that cannot be inadvertently connected to the regulator. Typically this system is connected to a three-way stopcock. The three-way stopcock is attached to the delivery catheter within the patient. The three-way stopcock can be used to equalize the pressure in the delivery syringe and avoid explosive delivery as well as excessive volume due to compression. The stopcock can also be used for the delivery of saline or contrast into the delivery catheter within the patient. The one-way valve at the end of the efferent tubing prevents retrograde flow of blood into the CO₂ delivery system.

Conclusion

The combination of a compact laboratory grade reusable CO₂ cylinder with a downsized regulator and a preassembled

closed delivery system provides a system that addresses all of the drawbacks of previous renditions of CO₂ delivery. The fact that it is safe, rapidly deployed, user friendly, with operator confidence will hopefully translate into greater use in the numerous clinical scenarios where it is either superior to liquid contrast or is a good adjunct to it. Hopefully, this additional tool will provide more successful procedures with less morbidity and mortality for patients.

References

- 1 Rotenberg E. Rontgenphotographie der leber, der Milz, und des Zwerchfells. *Dtsch Med Wochenschr* 1914;40:1205
- 2 Rosenstein P. Pneumoradiology of kidney position—a new technique for the radiological representation of the kidneys and neighboring organs (suprarenal gland, spleen, liver). *J Urol* 1921;15:447
- 3 Carlli HH. A new procedure for examining the kidney. *Rev Asoc Med Argent* 1921;34:18–24
- 4 Scatliff JH, Kummer AJ, Janzen AH. The diagnosis of pericardial effusion with intracardiac carbon dioxide. *Radiology* 1959; 73:871–883
- 5 Paul RE, Durant TM, Oppenheimer MJ, Stauffer HM. Intravenous carbon dioxide for intracardiac gas contrast in the roentgen diagnosis of pericardial effusion and thickening. *Am J Roentgenol Radium Ther Nucl Med* 1957;78(2):224–225
- 6 Hawkins IF. Carbon dioxide digital subtraction arteriography. *AJR Am J Roentgenol* 1982;139(1):19–24
- 7 Hawkins IF, Caridi JG. Carbon dioxide (CO₂) digital subtraction angiography: 26-year experience at the University of Florida. *Eur Radiol* 1998;8(3):391–402
- 8 Caridi J, Cho K, Furia C, et al. Carbon dioxide digital subtraction angiography (CO₂ DSA): a comprehensive user guide for all operators. *Vasc Dis Manag* 2014;11(10):E221–E256
- 9 Hawkins IF Jr, Caridi JG, Kerns SR. Plastic bag delivery system for hand injection of carbon dioxide. *AJR Am J Roentgenol* 1995; 165(6):1487–1489